

Review Article

Digital Smile Design – A Review

Kanwalpreet Kaur Bhullar¹, Shantun Malhotra², Jasneel Singh Grover³, Rupam Kaur⁴, Aashish Handa⁵, Mahima Malhotra⁶

¹Professor and Head, Department of Conservative Dentistry and Endodontics, Sri Guru Ram Das Institute of Dental Science and Research, Amritsar

²Reader, Department of Conservative Dentistry and Endodontics, Sri Guru Ram Das Institute of Dental Science and Research, Amritsar

³Post Graduate Student, Department of Conservative Dentistry and Endodontics, Sri Guru Ram Das Institute of Dental Science and Research, Amritsar

⁴Reader, Department of Conservative Dentistry and Endodontics, Sri Guru Ram Das Institute of Dental Science and Research, Amritsar

⁵Reader, Department of Conservative Dentistry and Endodontics, Sri Guru Ram Das Institute of Dental Science and Research, Amritsar

⁶Post Graduate Student, Department of Conservative Dentistry and Endodontics, Sri Guru Ram Das Institute of Dental Science and Research, Amritsar

ARTICLE INFO



Keywords: smile, dental esthetics, smile design, cosmetic dentistry, digital smile design

ABSTRACT

The two main objectives in Dental Esthetics are to create teeth of pleasing inherent proportions as well as to create a functional tooth arrangement that is in harmony with the gingiva, lips and face of the patient. Treatment planning in aesthetic dentistry can be improved by following standard procedures, routinely assessing recognised criteria to allow consistent results. Smile design is a relatively new discipline in the area of cosmetic dentistry as it involves multiple areas of evaluation for a proper treatment plan. The combination of the basic rules of esthetics together with the reflection of the facial analysis and the personality of the patient in the smile design creates a more natural and personalized smile.

Introduction

Esthetics is the branch of philosophy concerned with art and beauty. It can be described as a “well developed sense or perception of natural beauty.”⁽¹⁾ The perception of beauty as a corporal expression can vary from one individual to another, one civilization to another and from one ethnic group to another. Human beauty being a subjective matter changes the treatment modules of similar problems from one patient to another thus disallowing a standardization of the treatment plans.

In the past, the public’s and clinicians’ perception of dental esthetics was limited to modification of the individual teeth. However, although any type of tooth restoration could be performed as a single unit or in multiples, the cumulative visual impact of the anterior dentition often transcended the sum of the individual

parts. ⁽²⁾ Fortunately modern dentistry does not only provides us with better material and technology, but also ensures that today’s procedures are performed with minimum discomfort and maximum safety.

Esthetic treatment is highly subjective with active patient participation. It is very important to discuss at an early stage whether the patient is looking for a natural result in sympathy and harmony with their natural teeth. The goal in a natural smile is to achieve a pleasing balance between idealism and diversity, because in a subtle way, natural dentitions are always asymmetrical. This is subjective and requires judgement and skill, remembering that each smile is unique. The principles involved in making “pretty smiles” have come to be known within the profession as the discipline of smile

* Corresponding author: Dr. Kanwalpreet Kaur Bhullar Professor and Head, Department of Conservative Dentistry and Endodontics, Sri Guru Ram Das Institute of Dental Science and Research, Amritsar, Punjab, India, 143001. +91- 9815201712

design. Smile design theory can be broken down into at least four parts: facial esthetics, gingival esthetics, microesthetics and macroesthetics. Achieving a successful, healthy and functional result requires an understanding of the interrelationship among all the supporting oral structures.

Classification of Smiles⁽³⁾

- High
- Average
- Low

A high smile line reveals the total cervico-incisal length of the maxillary anterior teeth and a contiguous band of gingiva, whereas a low smile has less than 75% of display of the upper anterior teeth. In an average smile there is 75-100% display of the maxillary incisors with the incisal curvature of the maxillary anterior teeth paralleling the inner curvature of the lower lip and may be slightly or totally touching the lower lip. (Fig. 1)

Classification of Smile Styles⁽⁴⁾

Smile style is another soft-tissue determinant of the dynamic display zone.

There are three styles:

The cupid or commissure smile is characterized by the action of all the elevators of the upper lip, raising it like a window shade to expose the teeth and gingival scaffold.

The complex or full-denture smile is characterized by the action of the elevators of the upper lip and the depressors of the lower lip acting simultaneously, raising the upper lip like a window shade and lowering the lower lip like a window.

The Mona Lisa smile is characterized by the action of the zygomaticus major muscles, drawing the outer commissures outward and upward, followed by a gradual elevation of the upper lip (Fig. 2).

Goals of Smile Designing:

1. The goal of an esthetic makeover is to develop a peaceful and stable masticatory system, where the teeth, tissues, muscles, skeletal structures and joints all function in harmony.
2. To create teeth of pleasing inherent proportions, in themselves, as well as, to each other.
3. To create a pleasing tooth arrangement in harmony with the lips, gingival and face.

It is very important that when planning treatment for esthetic cases, smile design cannot be isolated from a comprehensive approach to patient care. Achieving a successful, healthy and functional result requires an understanding of the interrelationship among all the supporting oral structures⁽⁵⁾.

Diagnosis and Treatment Planning In Smile Design

Aesthetic treatment, like any other dental treatment, consists of four phases:

Phase 1: Systemic Phase

This phase starts before the treatment begins. Its purpose is to protect both the therapist as well as the patient. Risky patients, for example patients with diabetes mellitus and cardiovascular or blood diseases, are identified before

the actual treatment starts. This step includes consultations with the physician treating the patient.

Phase 2: Hygiene Phase

The goal of this phase is to establish a clean oral cavity to secure a healthy basis for the subsequent phase.

Phase 3: Corrective Phase

Dental and aesthetic corrections are carried out during this phase.

Phase 4: Maintenance Phase

During this phase, the finished reconstructions are checked as well as the overall health of the oral cavity.

Principles of Smile Design

The dental composition relates more specifically to teeth and their relationship to gingival tissues. A smile design should always include the evaluation and analysis of both facial and dental composition.

The two facial features which do play a major role in the smile design are:

- (i) **Interpupillary line**
- (ii) **Lips.**

The interpupillary line should be perpendicular to the midline of the face and parallel to the occlusal plane. Lips are important since they create the boundaries of smile design.

There are three aspects of the lip morphology that should be considered:

- Width
- Fullness
- Symmetry

Smile zone is the space that includes the teeth and tissues when inferior border of the upper lip and the superior border of the lower lip form an outline when smiling. The curvature of the lips as well as the prevalence of the shapes formed by the lips has been noted in texts. **There are six basic smile-zone shapes: straight, curved, elliptical, bow-shaped, rectangular, and inverted** (Fig. 3).

Tooth components of smile designing includes the dental midline which refers to the midline refers to the vertical contact interface between two maxillary central incisors. It should be perpendicular to the incisal plane and parallel to the midline of the face. Minor discrepancies between facial and dental midlines are acceptable. To evaluate the midline, one must always consider location and alignment.

Also the Incisal edge position determines the actual shape of the incisal edge and the best place to start designing the smile. ⁽⁶⁾ Maxillary incisal edge position is the most important determinant in smile creation because once set, it serves as a reference point to decide the proper tooth proportion and gingival levels.

The parameters used to establish the maxillary incisal edge position are:

- i) Degree of tooth display
- ii) Phonetics
- iii) Patient input

Various guidelines for establishing correct proportions in an esthetically pleasing smile are:

- 1. Golden proportion (Lombardi)**
- 2. Recurring esthetic dental proportions (Ward)**
- 3. M proportions (Methot)**
- 4. Chu's esthetic gauges**

1. Golden proportion (Lombardi) is viewed from the facial aspect, the width of each anterior tooth is 60% of the width of the adjacent tooth (mathematical ratio being 1.6:1:0.6). It is difficult to apply as patients have different arch form, lip anatomy and facial proportions.

2. Recurring esthetic dental proportion (Ward): The successive width proportion when viewed from the facial aspect should remain constant as we move posteriorly from midline. This offers great flexibility to match tooth properties with facial proportions

3. M proportions (Methot): This method compares the tooth width with the facial width using software. The whole analysis is done in the computer and hence involves more of mathematics rather than artistic analysis.

4. Chu's esthetic gauges: Dr. Chu's research supports Levin's RED concept and refutes the golden proportion. A series of gauges are available to make intraoral analysis easier.

Smile Guides

To minimize extended or failed delivery visits with removable or fixed prosthetics because of patient dissatisfaction with the smile design, several smile guides have been developed over the years⁽⁷⁾. These guides have attempted to serve as a communication tool to help the doctor understand what the patient wants, and for the doctor to communicate those desires to the laboratory. Nowadays, Computer design software has become the main communication technology between

dentists and ceramists and a useful tool for showing patients the possibilities for enhancing their smiles. There are new, step-by-step techniques for incorporating digital technology into the smile design process that can be accomplished in approximately three to four minutes. In the last two decades smile designing has progressively evolved from physical analogue to digital designing which has advanced from 2D to 3D.

Christian Coachman ⁽⁸⁾ in 2017 has proposed this evolution in generations as:

Generation 1: Analogue drawings over photos and no connection to the analogue model. It was the time when drawing with pen was done on printed copy of photographs to visualize the treatment result but that could not be correlated

with the study model. Digital dentistry by now was not introduced.

Generation 2: Digital 2D drawings and visual connection to the analogue model. With the advent of digital world, certain software like PowerPoint were familiarized which permitted digital drawing. Although not specific to dentistry and limited to drawing in two dimension it was more accurate and less time consuming than hand drawing. The drawing could be visually connected to the study model but physical connection still lacked.

Generation 3: Digital 2D drawings and analogue connection to the model. This was the beginning of digital-analogue connection. The very first drawing software specific to digital dentistry was introduced which linked 2D digital smile design to 3D wax-up. Facial integration to smile design was also introduced at

this stage, but connection to 3D digital world was missing.

Generation 4: Digital 2D drawings and digital connection to the 3D model. Now was the time when digital dentistry progressed from 2D to 3D analysis. 3D digital wax-up could be done involving facial integration and predetermined dental aesthetic parameters.

Generation 5: Complete 3D workflow.

Generation 6: The 4D concept adding motion to the smile design process.

Requirements for Digital Smile Design ⁽⁹⁾:

DSD technique is carried out by digital equipment already prevailing in current dental practice like a computer with one of the DSD software, a digital SLR camera or even a smart phone. A digital intraoral scanner for digital impression, a 3D printer and CAD/CAM are additional tools for complete digital 3D work flow.

An accurate photographic documentation is essential as complete facial and dental analysis rests on preliminary photographs on which changes and designing is formulated, a video documentation is required for dynamic analysis of teeth, gingiva, lips and face during smiling, laughing and talking in order to integrate facially guided principles to the smile design.

Photography Protocol includes the three frontal views, two profile views, A 12-o'clock view with a wide smile, an intra occlusal view of maxillary arch from second premolar to second premolar.

Videography Protocol includes the facial frontal video with retractor and without retractor smiling, a facial profile video with lips at rest and wide-E smile, a 12-o'clock video above the head at the most coronal angle.

Types of DSD software:

The clinician may follow any one of the given software:-

1. Photoshop CS6 (Adobe Systems Incorporated)
2. Microsoft Power Point (Microsoft Office, Microsoft, Redmond, Washington, USA)
3. Smile Designer Pro (SDP) (Tasty Tech Ltd)

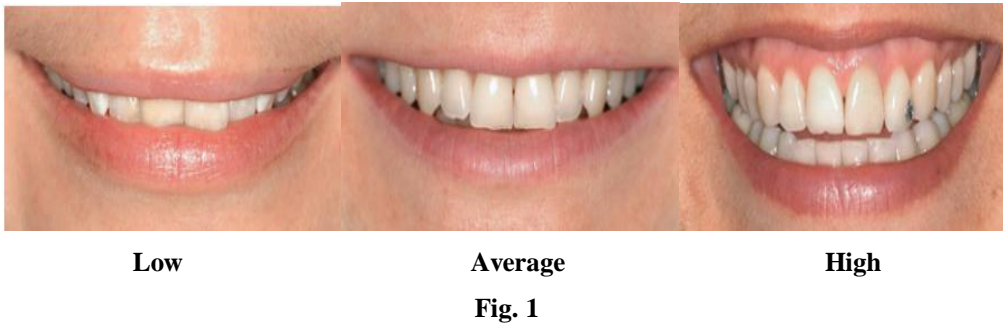Smile design involves many scientific principles that considered to create a beautiful smile. A cosmetic smile makeover has become a very popular procedure in the contemporary dentistry.

Applications of Digital Smile Design:

Applications of DSD includes the porcelain laminate veneers (Fig.4) which are steadily increasing in popularity among today's dental practitioners for conservative restoration for esthetics⁽¹⁰⁾, used as a planning tool for closure of midline diastema, in treatment planning of complex orthodontic cases, for gummy smile correction⁽¹³⁾ (Fig.5), treatment planning of molar-incisor hypomineralization⁽¹⁴⁾ (Fig.6), adjunct in rehabilitation of trauma cases, complex implant cases⁽¹⁵⁾, complete-arch implant-supported fixed prosthesis.

Limitations of Digital Smile Design

With the digital ruler, drawings, and reference lines, easy comparisons can be made between pre- and post-treatment photographs. But as the diagnosis and



Three smile styles:
A. Cuspid
B. Complex
C. Mona Lisa
Fig.2

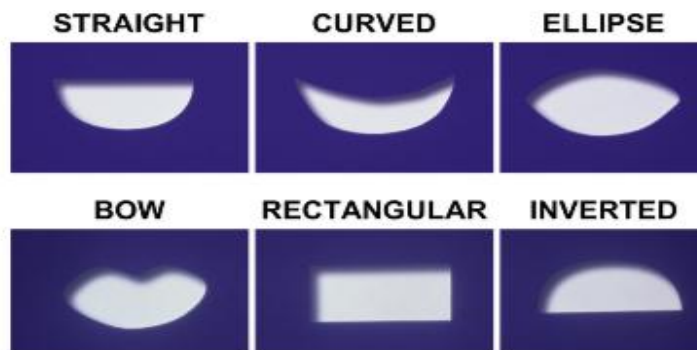
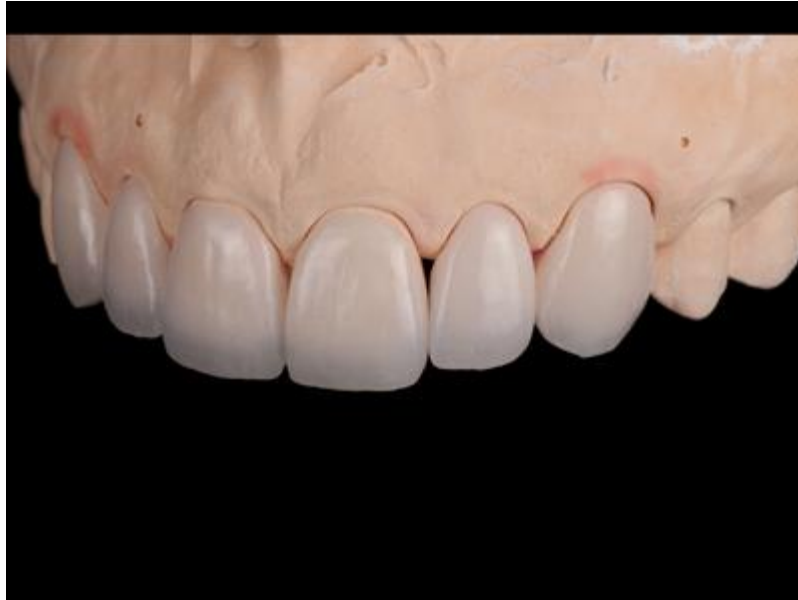
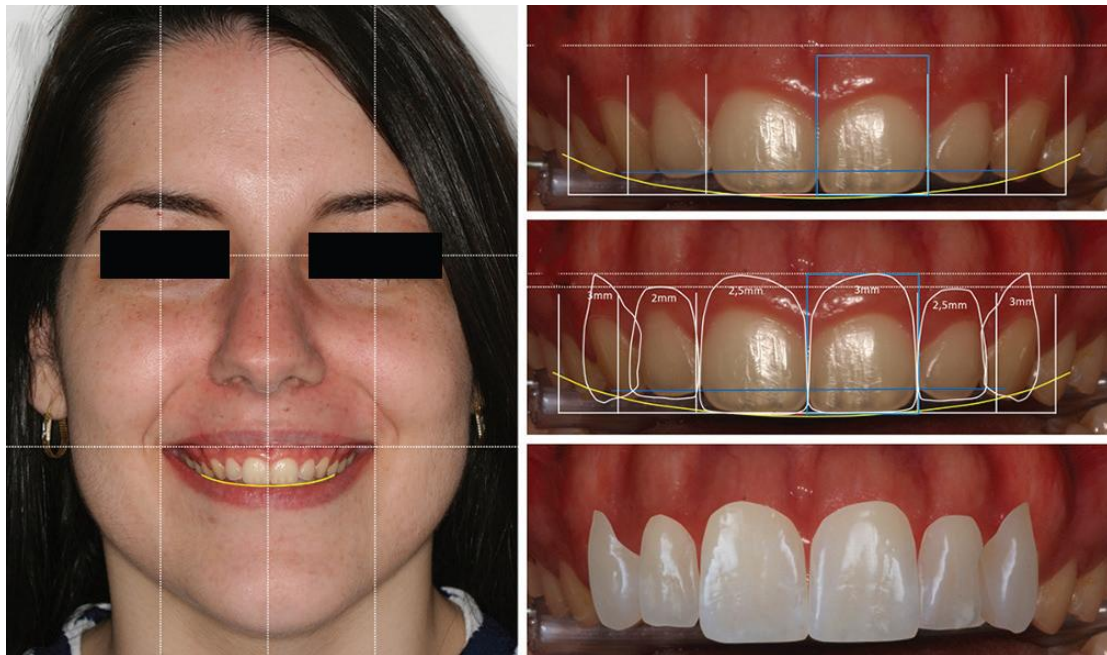
Fig.3



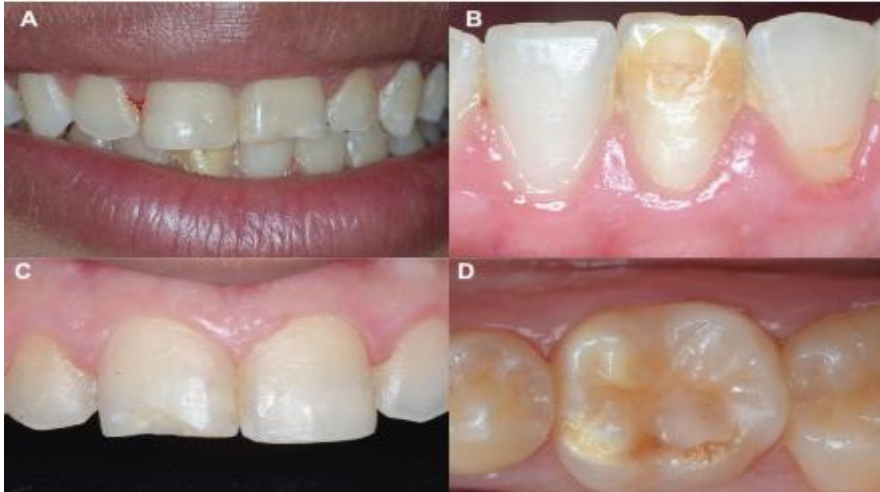Feldspathic porcelain veneers

Fig. 4



Reference lines for face and for each dental element resulting from digital smile design, allowing to determine the amount of gingiva to be removed during the surgical procedure and predictability of the final result

Fig. 5



A: The initial appearance of patient;

B- D: Teeth affected by MIH

Fig.6

treatment plan depends on photographic and video documentation, inadequacy in them may distort the reference image and may result in an incorrect diagnosis and planning.

Also for a complete 3D digital work flow, 3D softwares with updates, intraoral scanner, 3D printer and CAD/CAM are required which makes it economically expensive. Training and handling for certain software are necessary which further increases time and cost.

Future of Digital Smile Design

Complete 3D digital workflow is still not extensively used which in future may come into practice far and wide when more and more clinician will adopt digital scanner, 3D printers, CAD/CAM, then the need for time-consuming impressions, plaster and wax will become far less necessary. With the improvements in the software over the next few years, it will be possible to address

facial aesthetics in advanced cases where implants need to be placed by superimposing the files coming from a CT scan or a Cone Beam, along with 3D files of an oral impression or a facial scan and a photo. There also is a possibility of incorporating 4D concept in which motion can be added.

Conclusion

Digital imaging and designing helps patients to visualize the expected final result before the treatment itself starts which enhances the predictability of the treatment. The clinician can address patients concern by showing digitally the final outcome, motivating and educating them about the benefits of the treatment. It improves clinician diagnosis and treatment plan by aesthetic visualization of patients problem through digital analysis of facial, gingival and dental parameters that will analyze the smile and the face in an objective and standardized manner.

References:

1. Holyoak M. Smile design: rules, tools and strategies to help plan aesthetic restorative dentistry. *Primary dental journal*. 2013 Dec;2(4):38-43
2. Sharma PK, Sharma P. Dental smile esthetics: the assessment and creation of the ideal smile. In *Seminars in orthodontics*, WB Saunders. 2012 Sep 1 Vol.18, No. 3, pp. 193-201.
3. Tjan AH, Miller GD, The JG. Some esthetic factors in a smile. *The Journal of prosthetic dentistry*. 1984 Jan 1;51(1):24-28.
4. Ackerman MB, Ackerman JL. Smile analysis and design in the digital era. *J Clin Orthod*, 2002 Apr; 36(4): 221-36.
5. Bhuvaneshwaran M. Principles of smile design. *Journal of conservative dentistry*: 2010 Oct;13(4):225-232.
6. Mistry S. Principles of smile Demystified. *Journal of cosmetic dentistry* 2012; 28(2): 116-123.
7. Kayssoun A. Digital Smile Design. *Biomedical Journal of Scientific & Technical Research*. 2020;31(3): 187-200.
8. Coachman C, Calamita M. Digital smile design: a tool for treatment planning and communication in aesthetic dentistry. *Quintessence Dent Technol*. 2012;35:103–111.
9. Jafri Z, Ahmad N, Sawai M, Sultan N, Bhardwaj A. Digital Smile Design- An innovative tool in aesthetic dentistry. *Journal of oral biology and craniofacial research*. 2020 Apr 1;10(2):194-98.
10. Garcia PP, Da Costa RG, Calgareo M, Ritter AV, Correr GM, Da Cunha LF, Gonzaga CC. Digital smile design and mock-up technique for esthetic treatment planning with porcelain laminate veneers. *Journal of Conservative Dentistry*; 2018 Jul;21(4):455-58.
11. Pinzan-Vercelino CR, Pereira CC, Lima LR, Bramante FS, Pereira AL, Lima DM, Bandéca MC. Two-Year Follow-up of Multidisciplinary Treatment Using Digital Smile Design as a Planning Tool for Esthetic Restorations on Maxillary Midline Diastema. *IJO*. 2017;28(1) : 67-70.
12. Charavet C, Bernard JC, Gaillard C, Le Gall M. Benefits of Digital Smile Design (DSD) in the conception of a complex orthodontic treatment plan: A case report-proof of concept. *International orthodontics*. 2019 Sep1;17(3):573-79.
13. Levi YL, Cota LV, Maia LP. Digital smile design for gummy smile correction. *Indian Journal of Dental Research*. 2019 Sep 1;30(5):803-06.

14. Barreto SC, Soares VV, de Almeida Neves A, Nascimento DF, Maia LC, da Silveira Pereira GD. Molar Incisor Hypomineralization: the use of Digital Smile Design (DSD) in the Esthetic and Functional Recovery of Teeth. *Journal of Health Sciences*. 2020 Jun 30;22(2):135-41.

15. Haider KG. Digital Smile Design, Guided Surgery, Delivering Facial Driven Implant Treatment in A Failed Dentition: Case Reports. *On J Dent & Oral Health*. 2018;1(3): 1-7.